


PATIENT

Estrella Agosto

SPECIES

Canine

BREED

Miniature Schnauzer

SEX

Intact Female

Age

14 years

WEIGHT

#

INTERPRETED BY

 Remo Lobetti, BVSc,
 MMedVet (Med), PhD, Dipl.
 ECVIM

IMAGING PERFORMED BY

Sonya Myers, DVM

HOSPITAL NAME

 Oviedo Veterinary Care and
 Emergency

REFERRING VET

Dr Caja

INVOICE

303812

DATE

1/26/23

PRESENTING CLINICAL SIGNS

History: Hemorrhagic enteritis, severely depressed.

Physical Examination: N/A.

Urinalysis: N/A

CBC: N/A.

Serum Biochemistry: N/A.

Radiographic Findings: N/A.

ULTRASONOGRAPHIC EXAMINATION OF THE ABDOMEN
Urinary System

Full urinary bladder with a normal thickness and echogenic appearance of the wall. Normal anechoic urine with no sediment or uroliths evident.

Normal trigone area, proximal urethra (0.4 cm), and iliac blood vessels.

Normal iliac lymph nodes (1.3 cm). Ureters not visualized.

Normal renal size (left 5.2 cm, right 4.8 cm), echogenic appearance, cortico-medullary differentiation, pelvis, and capsule.

Reproductive System

Small amount of fluid and fluid pockets (1.4 cm) within the uterus but not distended (0.8 cm). Normal size and appearance of the ovaries (left 1.6 cm, right 1.4 cm).

Adrenal Glands

Normal position, echogenic appearance, shape, and size. Left 0.59/0.44 cm, right 0.4 /0.38 cm.

Spleen

Normal size (1.3 cm) and echogenic appearance. Smooth homogenous parenchyma, regular curvilinear capsule, and normal vasculature. No evidence of inflammatory, neoplastic, infarction, or infiltrative changes noted.

Liver

Normal size, echogenic and nodular appearance, portal markings, and regular curvilinear capsule. No nodules or masses evident. Full gall bladder containing small amount of hyperechogenic sediment. Normal thickness and echogenic appearance of the gall bladder wall. Normal bile duct (0.2 cm).


PATIENT
Gastrointestinal

Estrella Agosto

Normal appearance of the stomach, duodenum, small intestine, and ileo-cecal junction with no loss of layering, normal wall thickness (stomach 0.54 cm, duodenum 0.37 cm, jejunum 0.45 cm) and peristaltic activity, and no distension of the lumen. Thickening of the colon (0.64 cm) with no loss of layering or distension of the lumen. Ingesta within the stomach.

SPECIES

Canine

Pancreas
BREED

Miniature Schnauzer

Normal size (right 0.8 cm) and echogenic appearance. Regular capsule. Normal echogenic appearance of the mesentery and fat surrounding the pancreas.

SEX

Intact Female

Free Abdomen

Mesenteric lymphadenomegaly (0.8 x 3.1 cm) with normal shape and echogenic appearance. No ascites.

Age

14 years

ULTRASONOGRAPHIC FINDINGS

Primary Findings:

WEIGHT

#

- Colitis.
- Mesenteric lymphadenomegaly.
- Fluid within the uterus.

INTERPRETED BY

Remo Lobetti, BVSc,
MMedVet (Med), PhD, Dipl.
ECVIM

Secondary Findings:

- Gall bladder sediment.

IMAGING PERFORMED BY

Sonya Myers, DVM

INTERPRETATION OF THE FINDINGS & FURTHER RECOMMENDATIONS

Etiologies for the colitis would be acute hemorrhagic diarrhea syndrome, helminths, inflammatory bowel disease, ulcerative colitis, granulomatous colitis, and emerging neoplasia.

HOSPITAL NAME

Oviedo Veterinary Care and
Emergency

The most likely etiology for the lymph nodes would be reactive secondary to the intestinal disease with lymphadenitis and infiltrative neoplasia, less likely differential diagnoses.

REFERRING VET

Dr Caja

Etiologies for the uterus would be mucometra, hydrometra, pyometra, and cystic endometrial hyperplasia complex.

Further assessment would be fecal analysis and if there is not a satisfactory improvement with symptomatic therapy, then rectal cytobrush cytology, FNA cytology of the mesenteric lymph nodes, and colonoscopy with biopsies.

INVOICE

303812

Specific therapy would be dependent on an etiological diagnosis. Initial symptomatic therapy would be fluid therapy, intestinal diet, and intestinal binders/absorbents.

DATE

1/26/23



PATIENT

Estrella Agosto

SPECIES

Canine

BREED

Miniature Schnauzer

SEX

Intact Female

Age

14 years

WEIGHT

#

INTERPRETED BY

Remo Lobetti, BVSc,
 MMedVet (Med), PhD, Dipl.
 ECVIM

IMAGING PERFORMED BY

Sonya Myers, DVM

HOSPITAL NAME

Oviedo Veterinary Care and
 Emergency

REFERRING VET

Dr Caja

INVOICE

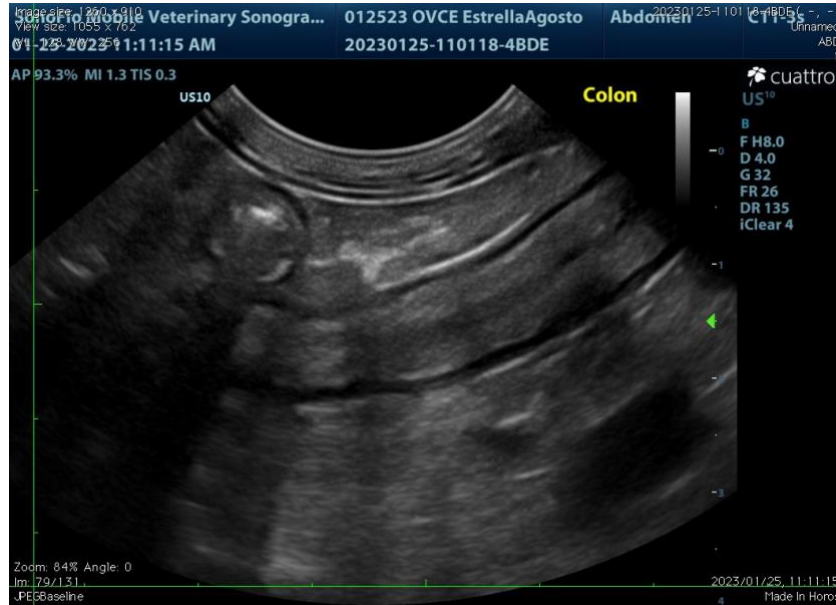
303812

DATE

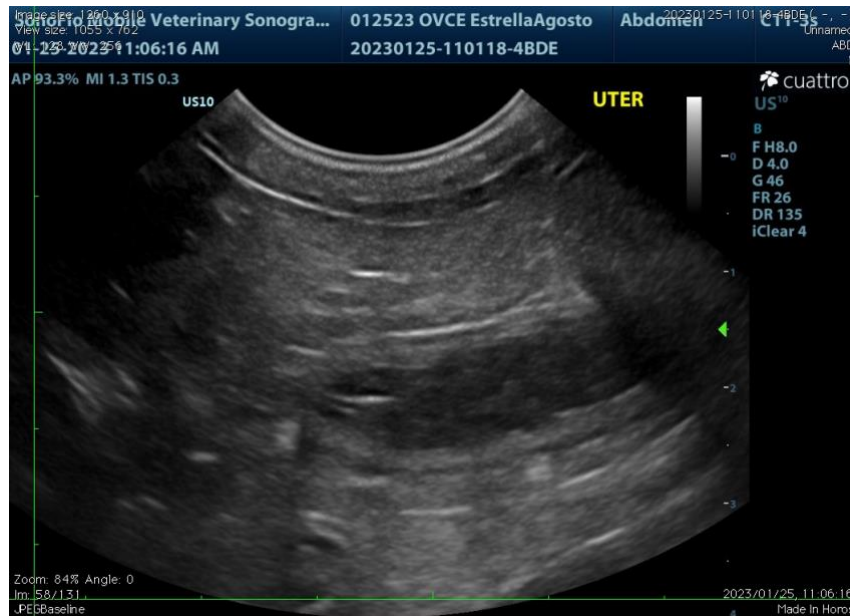1/26/23

IMAGES

Colon



Uterus





PATIENT

Mesenteric lymph node

Estrella Agosto

SPECIES

Canine

BREED

Miniature Schnauzer

SEX

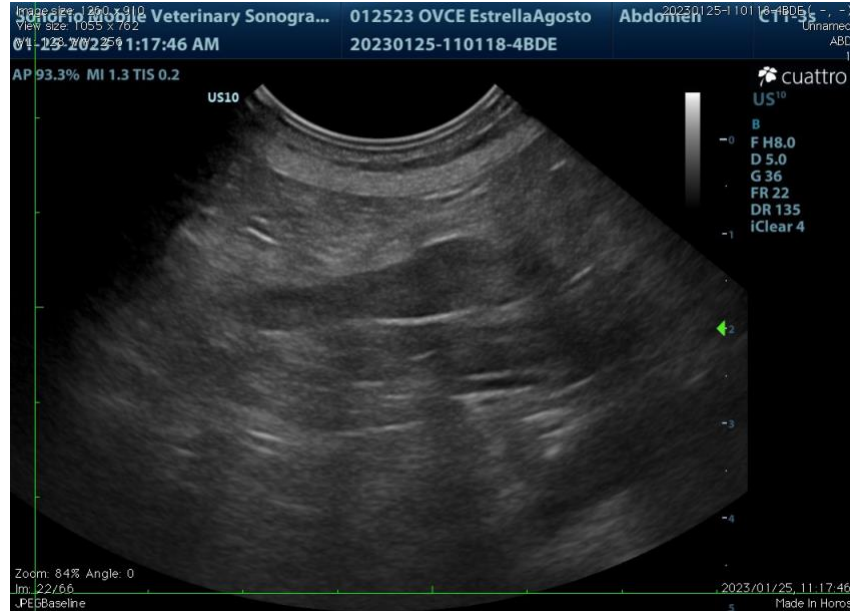Intact Female

Age

14 years

WEIGHT

#



INTERPRETED BY

Remo Lobetti, BVSc,
 MMedVet (Med), PhD, Dipl.
 ECVIM

The information and recommendations provided are based on the images presented by the referring veterinarian. No evaluation can be communicated regarding pathology that was not visible in the image/video clips provided.

Thank you for this referral. If the clinical or image interpretation does not parallel your findings or if I can be of any further assistance, please contact me.

Remo Lobetti, BVSc, MMedVet (Med), PhD, Dipl. ECVIM (Internal Medicine)
rlobetti@mweb.co.za

IMAGING PERFORMED BY

Sonya Myers, DVM

HOSPITAL NAME

Oviedo Veterinary Care and
 Emergency

REFERRING VET

Dr Caja

INVOICE

303812

DATE

1/26/23